



+ + +

Diagnosing intestinal parasite infections

Faecal Dx* antigen testing clinical reference guide

IDEXX

It is time to start testing pets

The European Scientific Counsel Companion Animal Parasites (ESCCAP) guideline 1 for worm control in dogs and cats lists two options for the diagnosis of intestinal worms: centrifugal flotation and antigen testing.¹ According to the ESCCAP diagnostic guideline 4, antigen testing can identify infections that can be missed by using another method (e.g. infections that are still prepatent) or increase the specificity in case of coprophagy.²

Gain client compliance with ESCCAP recommendations

As an alternative to repeated treatments, faecal examinations can be performed at suitable intervals followed by anthelmintic treatment where positive results are found. This approach should be adopted in countries where routine treatments are not acceptable for legislative reasons.¹ Regular coprological examination of faeces, at least 1–2 times yearly for group A and 4 times for group B as recommended by ESCCAP, is a good alternative to standard deworming advice. A dog's health and lifestyle may warrant more frequent testing. Let clients know that simply being outside puts a dog at risk. Some parasites can burrow into a dog's skin or feet. Dogs can also swallow parasites while grooming, nursing, or eating contaminated soil or faeces. Clients should also know that some infections can spread from pets to people.³

Recommend year-round, broad-spectrum parasite control

It is also important to test adult cats and dogs alongside antiparasitic treatments to demonstrate parasite control is effective and appropriate and that treatment is being applied correctly and at an effective frequency. Routine testing for intestinal nematodes is of benefit to practices both in terms of reinforcing good practice among pet owners, identifying which parasites are present in a local area, and surveillance for early detection of anthelmintic resistance.⁴

Diagnose and treat infections earlier with Faecal Dx* antigen testing

In summary, antigen testing offers an increase in sensitivity and specificity by detection of prepatent infection and demasking coprophagy, respectively.¹⁻⁴



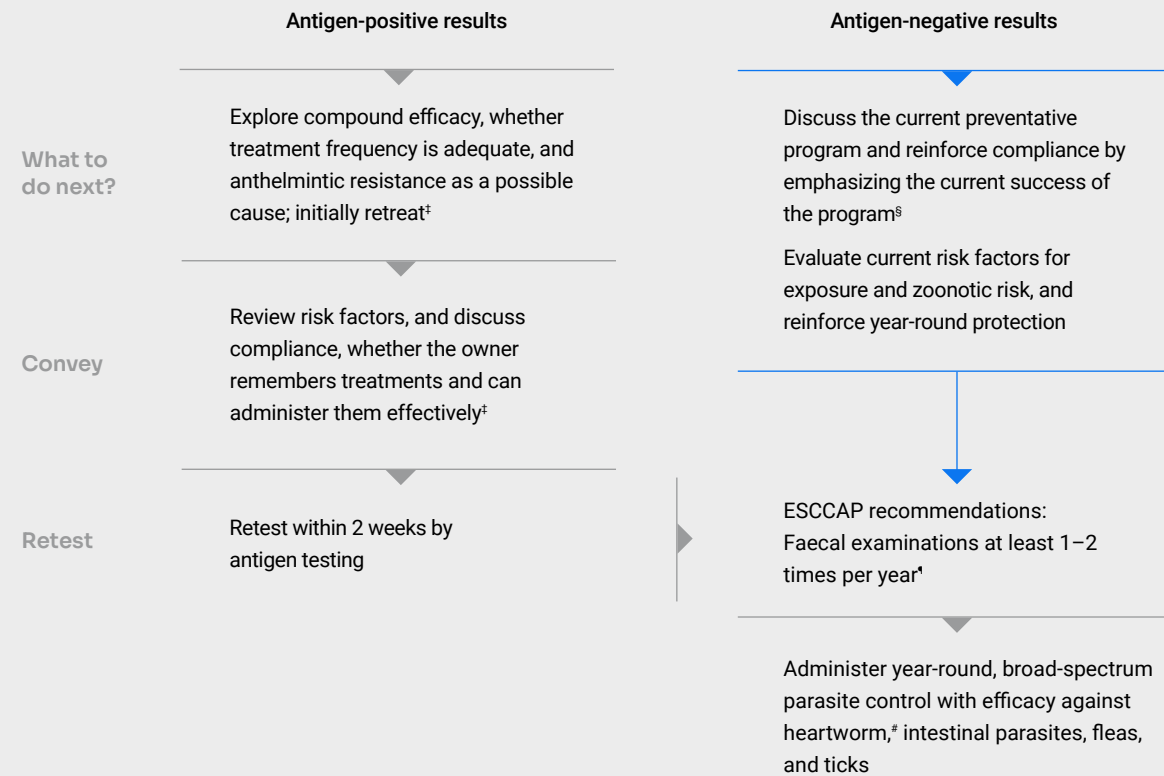
CREATING CLARITY



Faecal screening for healthy adult dogs

Diagnose hookworm, roundworm, whipworm, flea tapeworm and *Cystoisospora* using Faecal Dx* antigen testing. Because the testing detects antigens, positive results confirm the presence of worms and coccidia in the intestinal tract. This allows you to diagnose infection when worms are not shedding eggs or are caused by worms of a single sex.⁵⁻⁸ Use the following algorithm to guide next steps based on your patient's Faecal Dx antigen testing results.

What to do with your Faecal Dx antigen testing results†




†This algorithm takes into consideration guidance provided by ESCCAP UK & Ireland.⁴

‡Positive results in pets on preventative regimes shows also a need to investigate compliance on the part of the owner and potential causes of treatment failure (vomiting after tablet application, tablets not being eaten in food, spot-on applications being washed off, inadequate treatment frequency, inappropriate compound selection, drug resistance, etc). Parasites diagnosed in untreated pets demonstrates a need for treatment if the life stages found are zoonotic (*Toxocara*) or pathogenic (hookworm and whipworm).⁴

§There is also the perceived added value of clients getting their preventative care advice and treatments from veterinary practices rather than elsewhere.⁴

¶Regular coprological examination of faeces, as suggested in Groups A (1–2 times) and B (4 times), is a good alternative to standard deworming advice as recommended by ESCCAP guideline GL1 (Worm Control on Dogs and Cats): www.esccap.org/uploads/docs/oc1bt50t_0778_ESCCAP_GL1_v15_1p.pdf (accessed 17 January 2023).

*Administer heartworm anthelmintic treatment if pet resides in a heartworm-endemic country.





Did you know?

Treatment should be considered for patients that test positive by either antigen testing or egg/proglottid and oocyst detection.

Reasons for samples that are antigen positive and egg/proglottid/oocyst negative may include the following:

- + Absence of eggs, proglottids and oocysts during the prepatent period
- + Infections caused by single-sex worms
- + Intermittent egg/proglottid/oocyst shedding

Reasons eggs, proglottids and oocysts may be identified in samples that are antigen negative may include the following:

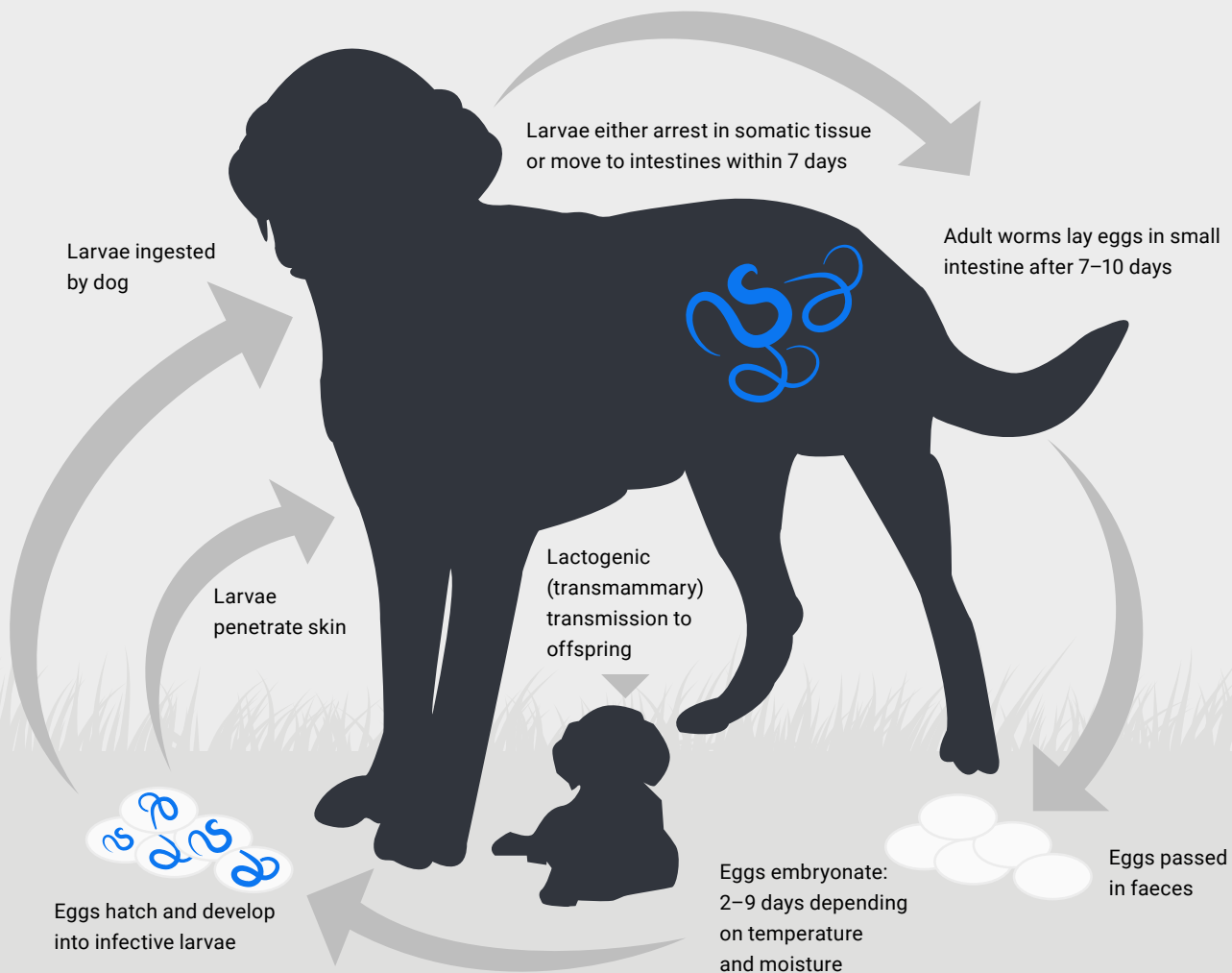
- + Ingestion of infected feces (coprophagy)
- + Antigen quantity is below the level of detection



Hookworms: from infection to presentation^{3,9-11}

Ancylostoma caninum life cycle*

Prepatent period for adult dogs: 15–26 days



*The prepatent period for *Uncinaria stenocephala* is usually 14–18 days, but it may require up to 4 weeks to reach patency; main transmission route is the oral uptake of infective larvae; in contrast to *Ancylostoma caninum*, it is unlikely that percutaneous infection contributes greatly to the life cycle; transplacental and transmammary transmissions apparently do not occur with *Uncinaria stenocephala*.^{9,11}

Clinical presentation

Pale mucous membranes and anemia; ill thrift, failure to gain weight; poor hair coat, dehydration; dark, tarry diarrhoea; respiratory disease; foot lesions (dermatitis with erythema, pruritus and papules).

Considering hookworms, the virulence is different between *Ancylostoma* spp. and *Uncinaria stenocephala*. The erythrocyte uptake as a direct cause of anemia is not a feature of *Uncinaria*, as well as dark, tarry diarrhoea, respiratory disease and foot lesions. *Uncinaria*, the most common hookworm in Europe, is a mucosal plug-feeder that ingests only small amounts of blood, and is thus less virulent, with the clinical signs encompassing ill thrift, failure to gain weight, poor hair coat, mucous diarrhoea (rarely bloody mucus) and hypoproteinemia with slight eosinophilia.⁸⁻¹⁰



Did you know?

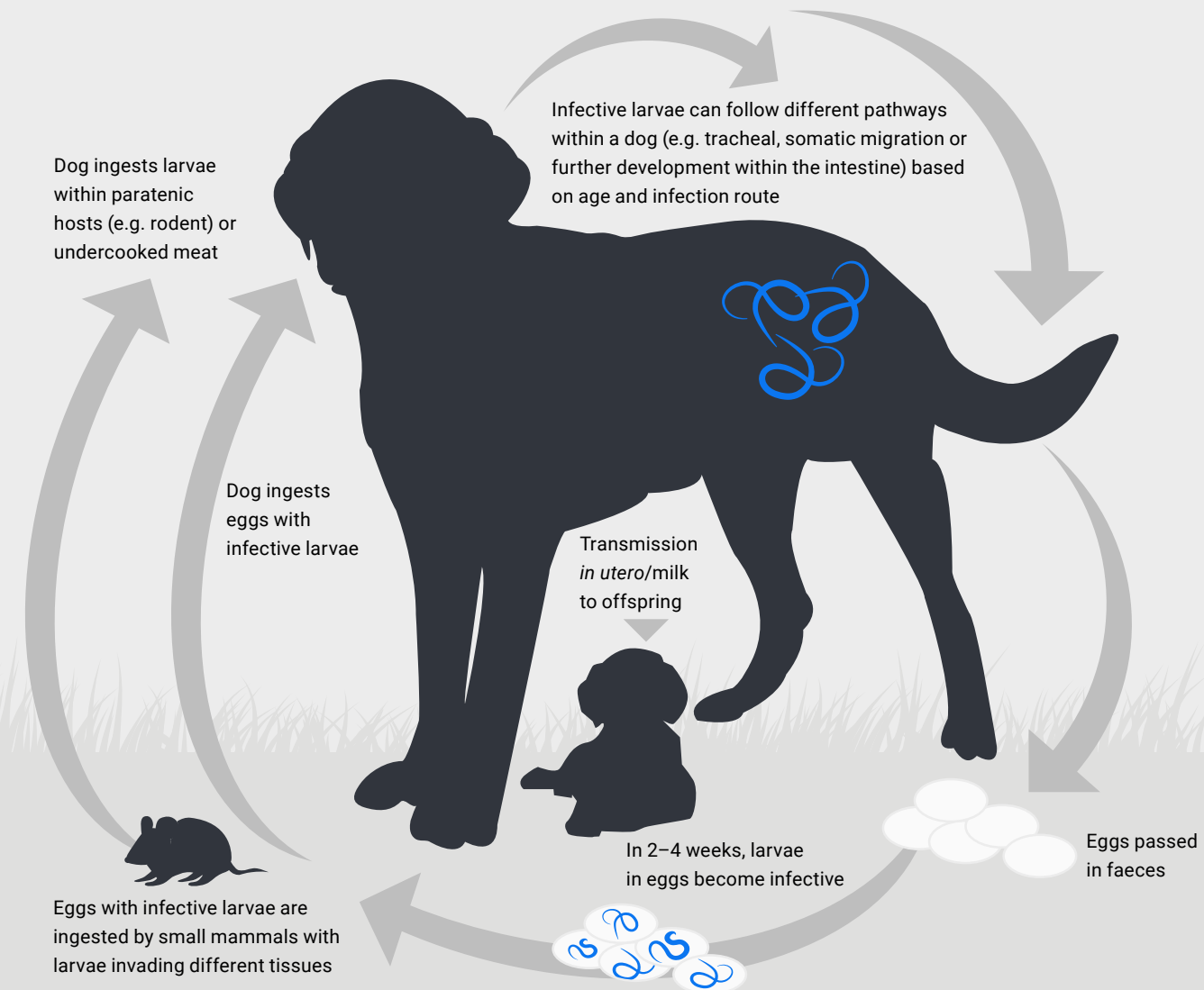
- + Because hookworms have short prepatent periods and the potential for arrested larvae, even pets receiving monthly deworming may have adult worms in their intestinal tract between monthly doses.⁹
- + Resistance to dewormers is now documented for *A. caninum* in North America.¹² Though, this is not documented so far in Europe. The responsiveness to treatment in *Uncinaria stenocephala* is different.¹³
- + Puppies as young as 10–12 days of age may start shedding eggs of *A. caninum* if they've been infected through nursing.⁹⁻¹¹
- + Due to the zoonotic risk and reinfection potential in this parasite, it is important to detect infections before they start shedding eggs into the environment.⁹⁻¹¹



Roundworms: from infection to presentation^{1,3,14}

Toxocara canis life cycle

Prepatent period for adult dogs: variable depending on infection route*



*The prepatent period typically occurs 16-21 days after prenatal infection, 27-35 days after lactogenic infection and 32-39 days after ingestion of eggs.¹

Did you know?


- + One female roundworm can produce 85,000 eggs per day, and these hard-shelled eggs can survive in the environment for years.^{3,14} With Faecal Dx* antigen testing, you can detect infections before roundworms start laying eggs.⁷⁻⁸
- + Due to the zoonotic risk and reinfection potential in this parasite, it is important to detect infections before they start shedding eggs into the environment.^{3,14}
- + In puppies under 6 months of age, studies have shown more than 30% are infected and shedding *T. canis* eggs.¹⁴



Clinical presentation

Diarrhea, vomiting, pot-bellied appearance, coughing. Dogs may cough up or vomit worms. Infections caused by *T. canis* are more common and most severe in dogs less than one year of age.



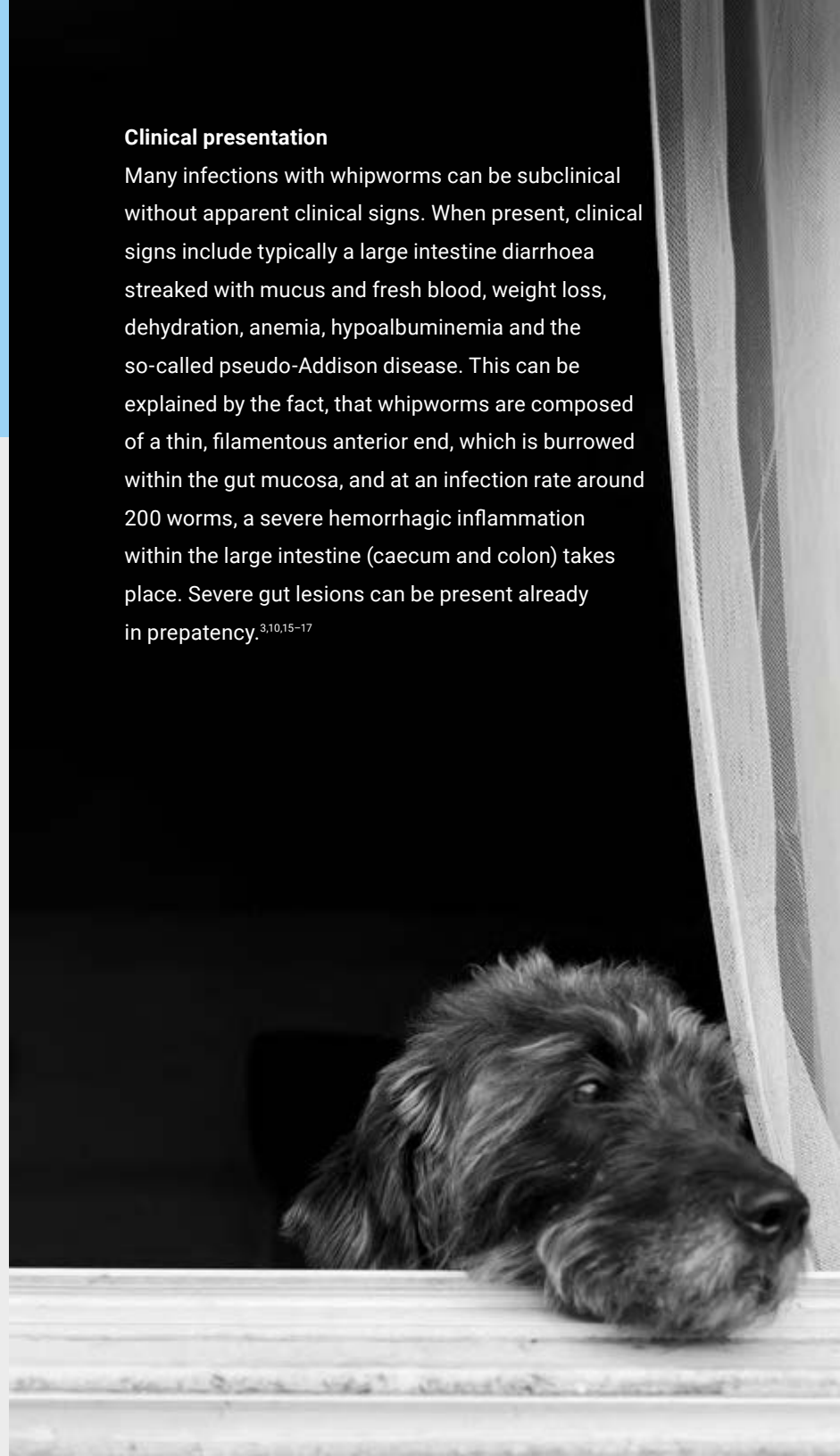


Clinical presentation

Many infections with whipworms can be subclinical without apparent clinical signs. When present, clinical signs include typically a large intestine diarrhoea streaked with mucus and fresh blood, weight loss, dehydration, anemia, hypoalbuminemia and the so-called pseudo-Addison disease. This can be explained by the fact, that whipworms are composed of a thin, filamentous anterior end, which is burrowed within the gut mucosa, and at an infection rate around 200 worms, a severe hemorrhagic inflammation within the large intestine (caecum and colon) takes place. Severe gut lesions can be present already in prepatency.^{3,10,15-17}

Did you know?

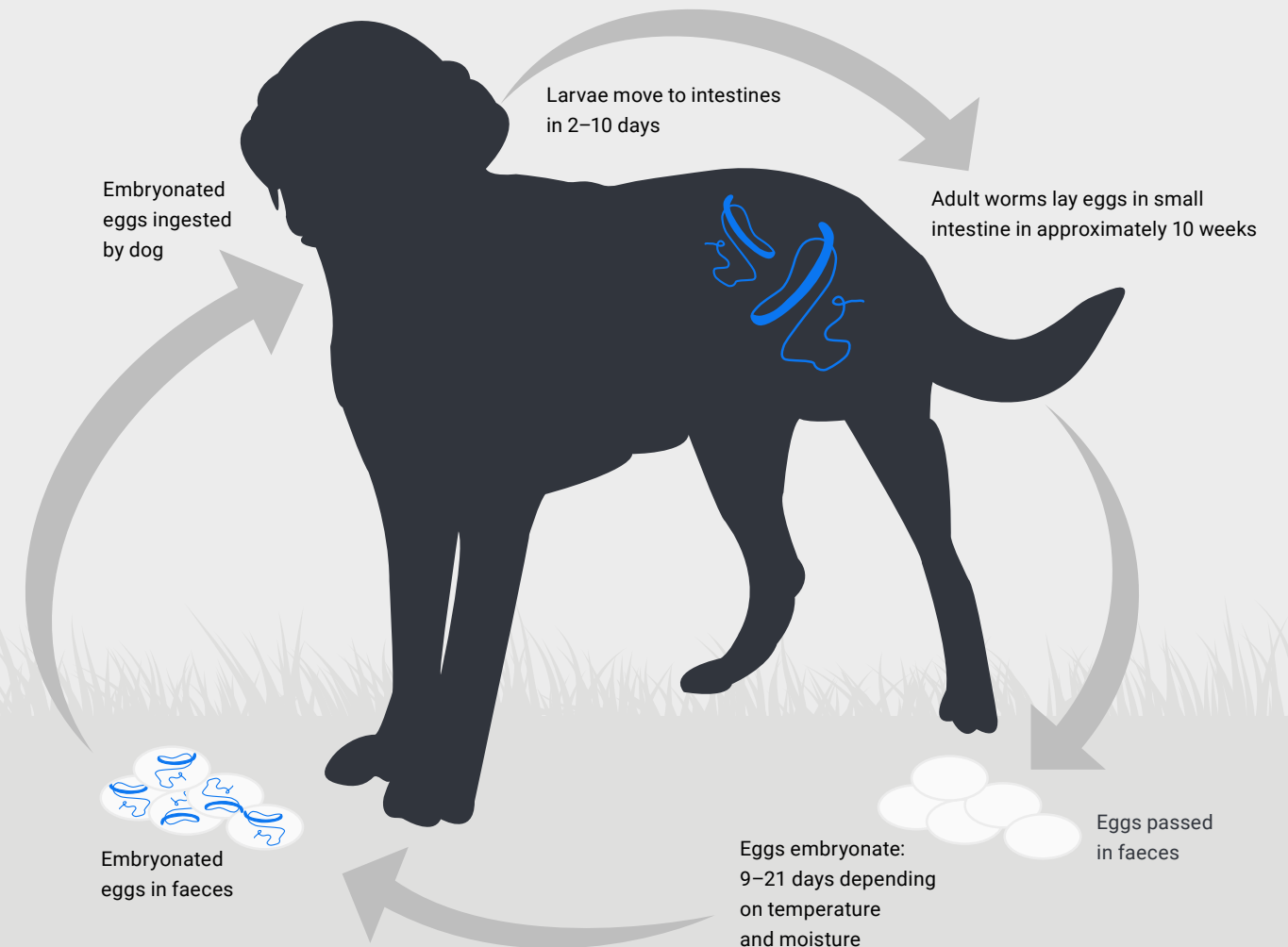
- + A female whipworm can produce as many as 2,000 eggs per day, and these infective whipworm eggs can survive in the environment for several years.¹⁵ With Faecal Dx* antigen testing, you can detect infections before whipworms start laying eggs.
- + Due to their extended prepatent period, it's unlikely to find eggs being shed in very young puppies,¹⁵ but Faecal Dx antigen testing can identify these positive patients during the prepatent period for earlier diagnosis and treatment.



Whipworms: from infection to presentation¹⁵

Trichuris vulpis life cycle

Prepatent period for adult dogs: 74–90 days



Clinical presentation^{3,10,18,19}

Dogs and cats with flea tapeworm infections rarely develop any clinical signs until they are present in large numbers. In cases with severe infection and in young animals, clinical signs can include neurological signs, unspecific abdominal signs with ill thrift and pot-bellied appearance, but also intestinal pleating and obstructions (the worm length can reach up to 70 cm). The passage of the proglottids may cause perianal irritation.

Did you know?

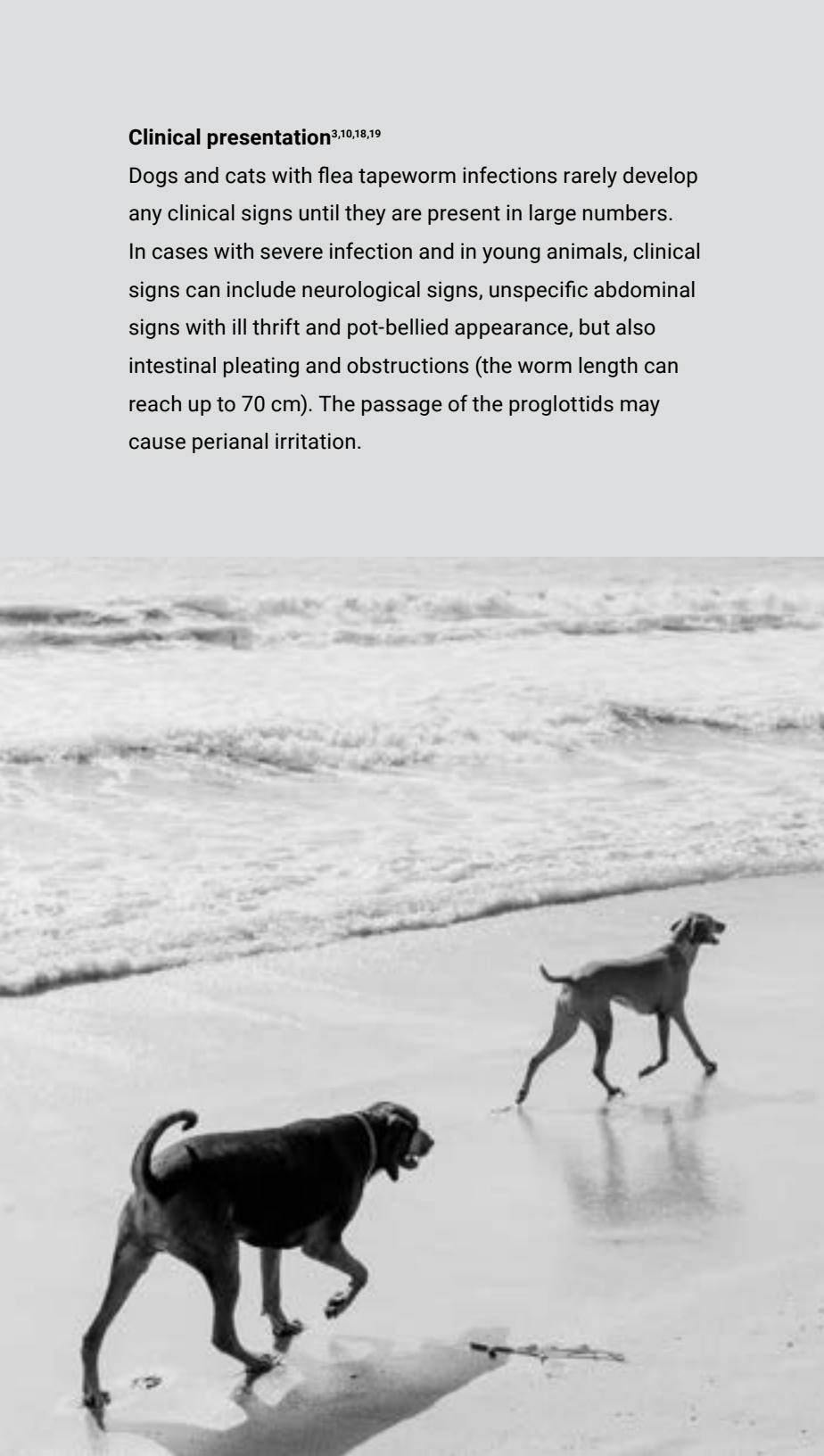
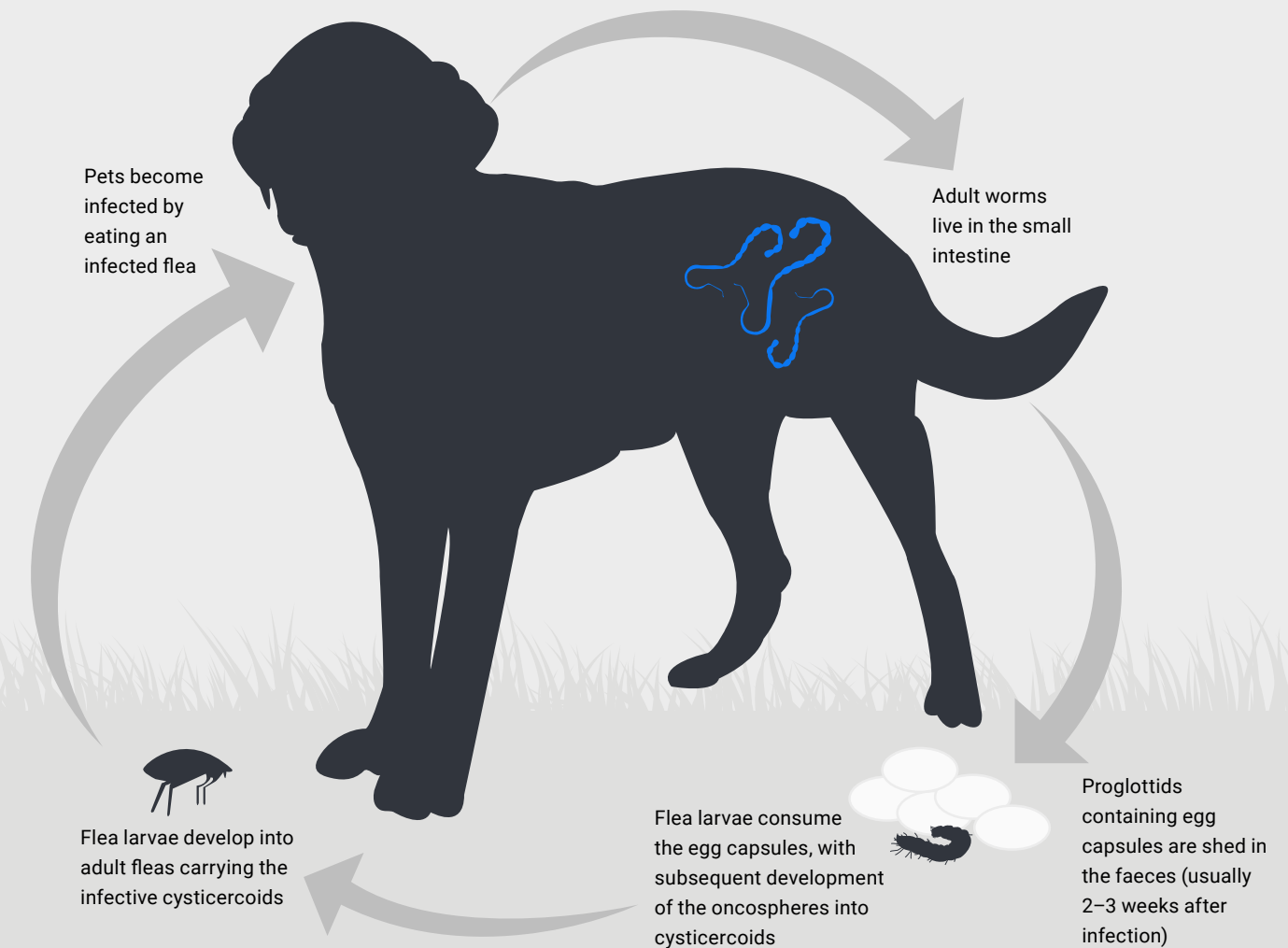
- + *D. caninum* is called the 'flea tapeworm' because the flea is its intermediate host.
- + Dogs and cats become infected by eating/ingesting an infected flea.
- + Each gravid segment (proglottid) of a flea tapeworm is packed with egg capsules, with every capsule containing 5–30 eggs.
- + Reinfection with *D. caninum* is likely if flea infestations are not controlled.
- + Dogs and cats may be infected with more than one species of tapeworm of the same family (e.g. *Diplopylidium* and *Joyeuxiella*), members of the family Taeniidae (e.g. *Taenia* or *Echinococcus*), or *Mesocestoides* species. Occurrence varies with region, detection method, dog or cat, lifestyle, diet and others.²⁰

Flea tapeworm: from infection to presentation^{18,19}

Dipylidium caninum life cycle

Prepatent period for adult dogs: 14–35 days^{18,19}

This tapeworm can infect dogs and cats and is spread through ingestion of infected fleas.

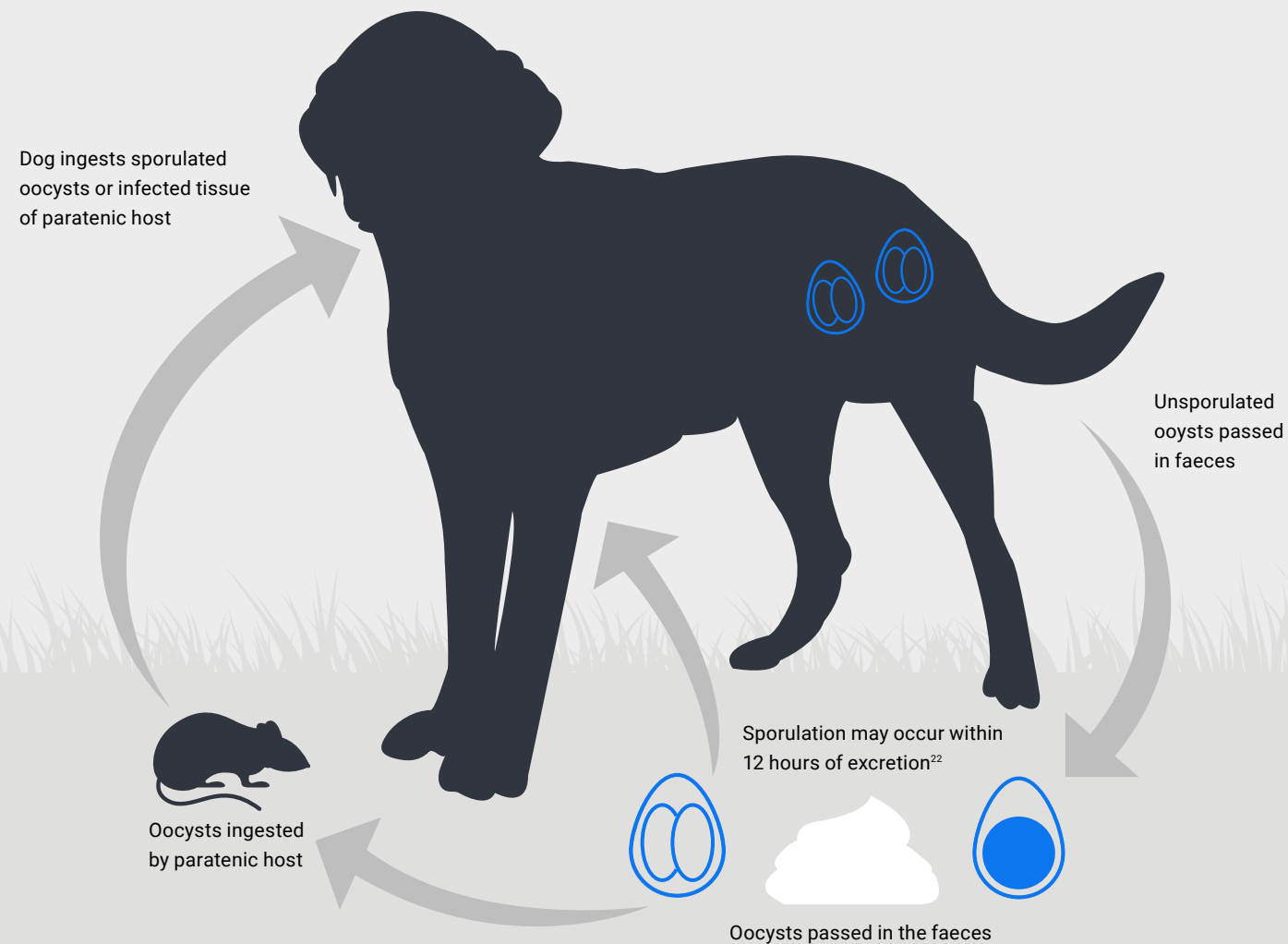


Cystoisospora canis: from infection to presentation²¹

Cystoisospora life cycle

Prepatent period 4–13 days²¹

This protozoa can infect dogs and cats and is spread through ingestion of oocysts in the environment or predation of an infected paratenic host.




Clinical presentation

Healthy adult dogs and cats may be infected and show no clinical signs. Young, stressed, and/or immunocompromised patients may have diarrhea, vomiting, dehydration, depression and anorexia.

Did you know?

- + Oocysts may survive up to a year in moist, protected conditions if freezing or excessively high temperatures are avoided.²¹
- + Oocysts of a pseudoparasite, *Eimeria* spp., are sometimes found in dog and cat feces.²¹ *Eimeria* oocysts might be confused with specific coccidia of dogs and cats without experience.
- + *Eimeria* is a coccidian parasite of rabbits, birds, and rodents but does not cause infection in dogs and cats.²¹



Faecal screening for sick dogs

Rule out infectious diseases by differentiating between acute uncomplicated (mild) diarrhoea and acute severe or chronic diarrhoea and testing accordingly. Testing recommendations vary based on the duration and severity of diarrhoea and the health and dietary habits of the dog or dogs affected. In acute uncomplicated (mild) diarrhoea cases of short duration, a *Giardia* antigen by immunoassay or the SNAP* *Giardia* Test is recommended in addition to Faecal Dx* antigen testing and faecal flotation by centrifugation. A more comprehensive diarrhoea profile, which also includes RealPCR* testing as an add-on panel and a microbiota dysbiosis index, is recommended in acute severe or chronic diarrhoea cases. Use the following algorithm to guide next steps when assessing sick dogs that present with diarrhoea.

Did you know?

RealPCR testing expands the scope of detection beyond nematode parasites, coccidia, *Giardia*, *Cryptosporidium* or pathogenic enterobacteria, allowing you to detect other important gastrointestinal pathogens, including viruses (up to four within the panel), *Clostridium* enterotoxins that include pore-forming netE and netF toxins (quantitatively), and difficult-to-detect protozoa (e.g. *Tritrichomonas foetus*).

How to protect pets from parasites

In addition to regular veterinary examinations and diagnostic screening, encourage your clients to follow ESCCAP guidelines.¹⁻⁴ Review parasite control in pets at least every 12 months as part of an annual health check.²³

Essential hygiene measures^{1,23}

Food and water

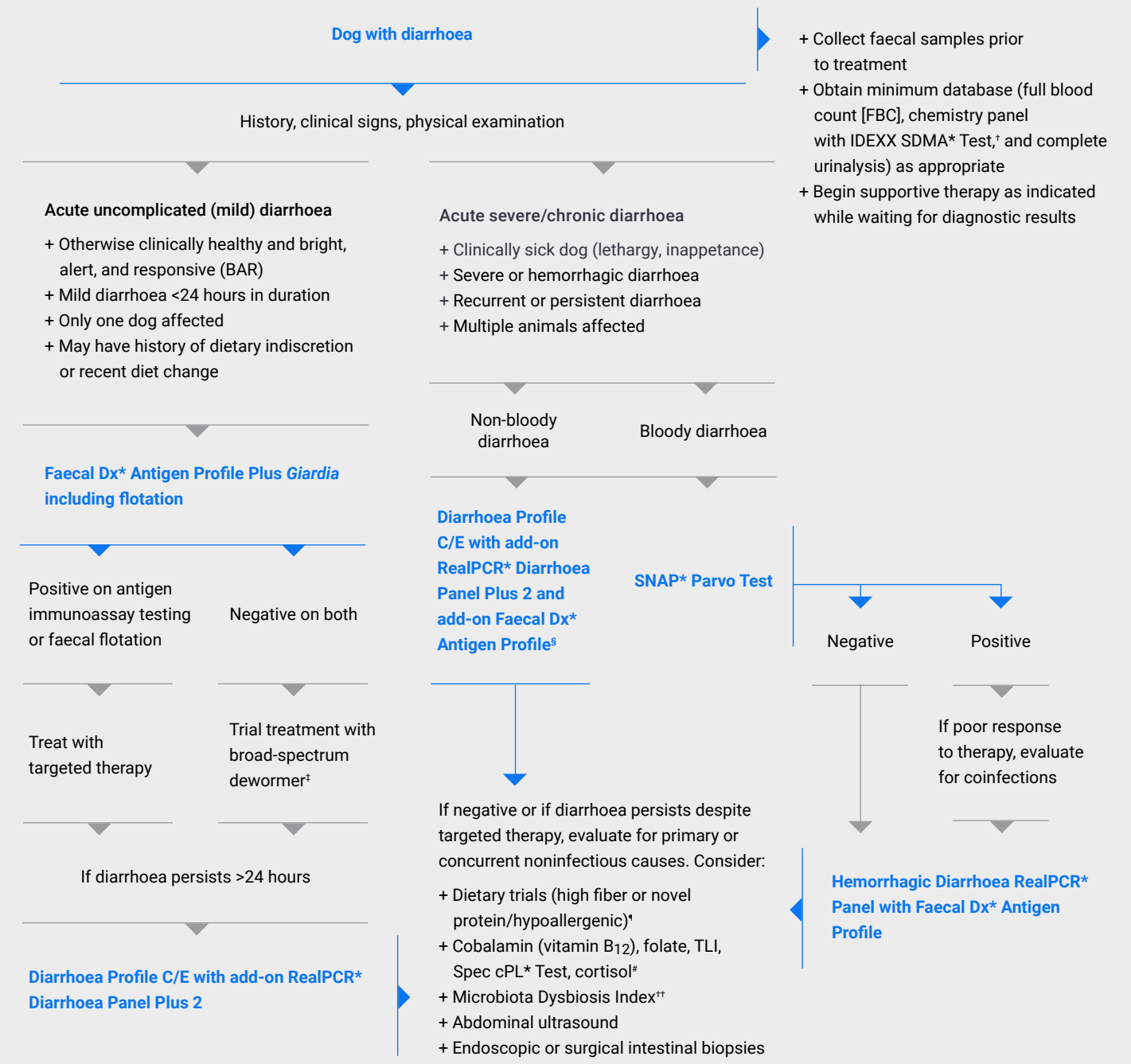
- + Unprocessed raw meat diets are not recommended.
- + Make sure pets have access to fresh water.
- + Thoroughly wash all fruit and vegetables before eating.

Outdoor activity

- + Preventing infection by reducing, where possible, the risk of the pet acquiring infection.
- + Cover sandboxes after use.

Hygiene

- + Wash hands immediately after incidental contact with faeces.
- + Promptly pick up and dispose of faeces from public areas.
- + Promptly remove faeces from the yard.
- + Dog and cat waste should not be composted if compost is intended for edible crops.



*CRP (test code CRPI) can be a valuable add-on option (test code CRPIS) when encountering systemic inflammation associated with diarrhoea.

†Most cases of acute uncomplicated (mild) diarrhoea are self-limiting within 2–4 days. Consider also highly digestible intestinal diet, antiemetics, probiotics and prebiotics.

‡Diarrhoea Profile C/E with test codes PROF/C/PROFE, and add-on RealPCR Diarrhoea Panel Plus 2 with test code PDFP2S, and Faecal Dx Antigen Profile (without *Giardia*) with test code NEMAES.

§With the addition of appropriate probiotics and prebiotics and other products based on specific diagnosis (e.g. EPI, PLE, IBD, hypoadrenocorticism, granulomatous colitis or dysbiosis).

†Available as Canine Gastrointestinal Disease Profile (test code PROFFPH) and also as add-on panel (test code PROFFPHS). The serum basal cortisol is contained to exclude atypical hypoadrenocorticism.

††Canine Microbiota Dysbiosis Index: 7 PCR tests for *Clostridium hiranonis*, *Blautia*, *E. coli*, *Faecalibacterium*, *Fusobacterium*, *Streptococcus*, *Turicibacter* (canine composition) and includes interpretation of the calculated dysbiosis index (test code DYSBIND).



References

1. ESCCAP Guideline 01 Sixth Edition – May 2021: Worm Control in Dogs and Cats. European Scientific Counsel Companion Animal Parasites; 2021. Accessed February 8, 2023. www.esccap.org/uploads/docs/oc1bt50t_0778_ESCCAP_GL1_v15_1p.pdf
2. ESCCAP Guideline 04 First Edition – November 2022: Parasitological Diagnosis in Cats, Dogs and Equines. European Scientific Counsel Companion Animal Parasites; 2022. Accessed February 8, 2023. www.esccap.org/uploads/docs/hgqo8xak_1335_ESCCAP_GL4_v2_1p.pdf
3. ESCCAP Modular Guide Series 01 Third Edition: Worm Control in Dogs and Cats [adapted from ESCCAP Guideline 01 Sixth Edition – May 2021: Worm Control in Dogs and Cats]. European Scientific Counsel Companion Animal Parasites; 2021. Accessed February 8, 2023. https://www.esccap.org/uploads/docs/uoayqf2a_0461_ESCCAP_MG1_English_20210518.pdf
4. ESCCAP UK & Ireland. Intestinal Nematodes: Ascarids, Hookworms and Whipworms: Considerations for Routine Diagnostic Screening. European Scientific Counsel Companion Animal Parasites. Accessed February 8, 2023. www.esccapuk.org.uk/uploads/docs/veh93bk1_FINAL_Diagnostic_testing_poster.pdf
5. Adolph C, Barnett S, Beall M, et al. Diagnostic strategies to reveal covert infections with intestinal helminths in dogs. *Vet Parasitol*. 2017;247:108–112. doi:10.1016/j.vetpar.2017.10.002
6. Elsemore DA, Geng J, Flynn L, Cruthers L, Lucio-Forster A, Bowman DD. Enzyme-linked immunosorbent assay for coproantigen detection of *Trichuris vulpis* in dogs. *J Vet Diagn Invest*. 2014;26(3):404–411. doi:10.1177/1040638714528500
7. Elsemore DA, Geng J, Cote J, Hanna R, Lucio-Forster A, Bowman DD. Enzyme-linked immunosorbent assays for coproantigen detection of *Ancylostoma caninum* and *Toxocara canis* in dogs and *Toxocara cati* in cats. *J Vet Diagn Invest*. 2017;29(5):645–653. doi:10.1177/1040638717706098
8. Hauck D, Raue K, Blazejak K, et al. Evaluation of a commercial coproantigen immunoassay for the detection of *Toxocara cati* and *Ancylostoma tubaeforme* in cats and *Uncinaria stenocephala* in dogs. *Parasitol Res*. 2023;122(1):185–194. doi:10.1007/s00436-022-07715-0
9. CAPC guidelines: hookworms. Companion Animal Parasite Council. Updated September 12, 2022. Accessed February 8, 2023. www.capcvet.org/guidelines/hookworms
10. Bowman DD, Hendrix CM, Lindsay DS, Barr SC. *Feline Clinical Parasitology*. Iowa State University Press; 2002.
11. Anderson RC. *Nematode Parasites of Vertebrates: Their Development and Transmission*. 2nd ed. CABI Publishing; 2000:650.
12. Jimenez Castro PD, Howell SB, Schaefer JJ, Avramenko RW, Gilleard JS, Kaplan RM. Multiple drug resistance in the canine hookworm *Ancylostoma caninum*: an emerging threat? *Parasit Vectors*. 2019;12(1):576. doi:10.1186/s13071-019-3828-6
13. Vrhovec MG, Alnassan AA, Pantchev N, Bauer C. Is there any change in the prevalence of intestinal or cardiopulmonary parasite infections in companion animals (dogs and cats) in Germany between 2004–2006 and 2015–2017? An assessment of the impact of the first ESCCAP guidelines. *Vet Parasitol*. 2022;312:109836. doi:10.1016/j.vetpar.2022.109836
14. CAPC guidelines: ascarid. Companion Animal Parasite Council. Updated September 12, 2022. Accessed February 8, 2023. www.capcvet.org/guidelines/ascarid
15. CAPC guidelines: *Trichuris vulpis*. Companion Animal Parasite Council. Updated September 12, 2022. Accessed February 8, 2023. www.capcvet.org/guidelines/trichuris-vulpis
16. Venco L, Valenti V, Genchi M, Grandi G. A Dog with pseudo-Addison disease associated with *Trichuris vulpis* infection. *J Parasitol Res*. 2011;2011:682039. doi:10.1155/2011/682039
17. Kirkova Z, Dinev I. Morphological changes in the intestine of dogs, experimentally infected with *Trichuris vulpis*. *Bulg J Vet Med*. 2005;8(4):239–243.
18. CAPC guidelines: *Dipylidium caninum*. Companion Animal Parasite Council. Updated September 12, 2022. Accessed February 8, 2023. www.capcvet.org/guidelines/dipylidium-caninum
19. Rousseau J, Castro A, Novo T, Maia C. *Dipylidium caninum* in the twenty-first century: epidemiological studies and reported cases in companion animals and humans. *Parasit Vectors*. 2022;15(1):131. doi:10.1186/s13071-022-05243-5
20. Globokar Vrhovec M. *Retrospektive Analyse der parasitologischen Untersuchungsergebnisse eines privaten Untersuchungslabors: Intestinale, respiratorische und vektorübertragene Parasitosen bei Hunden und Katzen in Deutschland (2004–2006)*. Dissertation. Justus-Liebig-Universität Gießen; 2013.
21. Companion Animal Parasite Council. CAPC Guidelines: Coccidia. Updated October 1, 2016. Accessed April 18, 2024. www.capcvet.org/guidelines/coccidia
22. Lappin MR. Isosporiasis. In: Sykes JE, ed. *Canine and Feline Infectious Diseases*. WB Saunders; 2014:793–796. doi:10.1016/B978-1-4377-0795-3.00082-X
23. *How to Protect Pets from Parasites*. European Scientific Counsel Companion Animal Parasites. Accessed February 8, 2023. https://www.esccap.org/uploads/docs/t58tbu33_0687_ESCCAP_General_Recommendations_update_v5.pdf